

## Improvement of the Aesthetic Outcome and Reduction of the Donor Site Morbidity in Autogenous Microtia Reconstruction

SALAH NASSER, M.D.

*The Department of Plastic and Reconstructive Surgery, Faculty of Medicine, Ain Shams University, Cairo.*

### ABSTRACT

In an attempt to improve the aesthetic outcome and to minimize the donor site morbidity in autogenous microtia repair, multiple modifications on the two-stage technique were developed and presented in this article. In the first stage, lobule transposition, fabrication and implantation of the cartilage framework were performed. During this stage, some modifications were performed to improve the aesthetic outcome; (1) rapid intraoperative tissue expansion for the pocket skin, (2) extra-thinning for the base of the framework with more augmentation for the helix and antihelix and (3) use of negative suction drainage in addition to the bolster sutures to induce good coaptation of the skin to the framework. To minimize the donor site deformity, two more steps were executed (4) a small rim from the 6<sup>th</sup> costal cartilage was left attached to the 5<sup>th</sup> rib and (5) the floating 8<sup>th</sup> rib was splitted in its proximal part keeping rim from it in place. In the second stage, elevation of the auricle, projection augmentation with banked crescent shape cartilage graft tunneled under the mastoid fascia. During this stage, two more additional modifications were performed where, (6) the incision for framework delivery and plane of dissection were adjusted to maintain the integrity of the posterior hairline and (7) the cartilage graft was tunneled under the mastoid fascia to avoid harvesting of the temporo-parietal fascia. A total of 16 ears in 15 patients with microtia were treated. All the patients presented good acceptable ear contour. Unfavorable results were diminished convolutions of the reconstructed auricle in one patient, improper projection in two, helical notch in one and hypertrophic scars in two patients. No visible donor site deformity encountered. In conclusion, the results of the two stage reconstruction with the mentioned modifications produced favorable aesthetic results with minimal donor site morbidity.

### INTRODUCTION

Reconstruction of the microtic ear represents one of the most demanding challenges in reconstructive surgery [1]. Materials for auricular reconstruction are autogenous cartilage [2-17] and artificial implants [18-19]. Despite their potential for donor-site complications, autogenous cartilage frameworks remain the gold standard for external ear reconstruction [20]. A variety of surgical strategies have been devised for the reconstruction of

the external ear, with each composed of several stages. The stages depend largely on the severity of the patient's deformity; the size, position and quality of the microtic elements and the surgeon's preference [1]. Gillies, in 1920, first described using costal cartilage grafts in reconstructing the auricle [21]. Tanzer popularized the use of autogenous rib cartilage for reconstruction [2,3]. These techniques have been further refined by Brent [4-8], Nagata [9-13], Firmin [14] and others, over the last three decades. Brent reported a four-stage technique for ear reconstruction and he obtained outstanding results using various modifications of detailed surgical techniques. Nagata [9-13] and Park [15,16] reported a two-stage and single-stage technique for ear reconstruction, respectively. Currently, the basic steps in microtia repair require, on average, three to four stages involving the use of the patient's rib cartilage to carve a framework which is implanted under the skin. Subsequent stages involve creating a lobule, separating the reconstructed auricle from the head and construction of a tragus. This method of autogenous cartilage graft repair is chosen for its quality, reproducibility and patient satisfaction. However, ideal results are not always achieved, and there continue to be drawbacks with the standard approach to reconstruction with autogenous rib cartilage [22]. Multiple surgical procedures with the associated anesthetic risk are required to complete the reconstruction.

Donor site morbidity related to harvest of the rib cartilage includes the risk of pneumothorax, significant initial postoperative pain, scarring and a visible chest wall deformity in most patients [22]. These shortcomings have promoted surgeons to continually refine and modify techniques used for microtia reconstruction. In this article, we present the two stage technique of Nagata for congenital

microtia repair and the modifications we have developed to improve the aesthetic outcome and minimize the morbidity.

## MATERIAL AND METHODS

Fifteen patients with sixteen microtic ears were included in this study. They were 12 males and 3 females. Their ages ranged between 6 and 23 years. All the patients had unilateral microtia except one patient with bilateral deformity. Ten ears showed the classic lobule-type deformity, four with the concha-type and two presented with the small concha-type deformity according to the classification proposed by Nagata [10]. Hemi-facial microsomia grade one was associated clinical anomaly in three patients and treacher-Collins syndrome in one patient. The following describes the standard two-stage technique [9] with some technical modifications in every stage to reduce donor site complications and to improve the aesthetic outcome.

1- First Stage: (Lobule rotation, pocket creation and framework fabrication with contralateral rib cartilage).

### 1.1- Preoperative planning:

A pattern for the construct was made by placing a piece of X-ray film against the normal ear in unilateral cases or the parent's ear in bilateral cases and tracing its anatomical landmarks. The template was then reversed and a new one was made several millimeters smaller throughout to accommodate for the thickness of the skin cover. Once configured, the template was aligned symmetrically with the contralateral ear using the ear's relationship to the nose, lateral canthus and position of the lobule. In patients with hemifacial microsomia, the difference in height of both sides of the face and the antero-posterior dimensions were considered in determining the new ear's location. The template was then traced on the head to mark the pocket site.

### 1.2- Lobule rotation:

The procedure is started with transposition of the lobule. The line of incision for rotation of the lobule was determined according to the lobule remnant. In the lobular type deformity, the earlobe is transposed from its anterior position using the remnants of the microtic ear to build a lobule. This transposition can be done in the form of an asymmetric Z-plasty. The lobule is advanced to cover the caudal tip of the framework as this makes a smooth transition from the framework to the lobule.

### 1.3- Creation of the skin pocket:

Dissection of the auricular pocket starts by excision of the entire amorphous cartilage, while

preserving the subdermal plexus. The field of dissection should be one cm at least, beyond the outline, to afford adequate drape of the skin flaps over the framework without undue tension. After dissection of the pocket, rapid intra-operative skin expansion using Foley's catheter during the carving of the framework was performed. This expansion improves the skin pliability and helps the skin to drape well over the three dimensional framework. In conchal type microtia, the incisions are modified to make maximal use of the additional skin available.

### 1.4- Auricular framework fabrication with contralateral rib cartilage:

The contra-lateral sixth, seventh and eighth costal cartilages were harvested preserving a minimal rim of the upper margin of the 6<sup>th</sup> rib cartilage. Also, the floating 8<sup>th</sup> rib was splitted in place, leaving about one third of its lower part attached in place (Fig. 1). The construct base was formed by synchondrosis of the sixth and seventh cartilages and was carved as thin as possible with exaggerated details. A four- to five cm long lateral segment of the seventh cartilage was used to fabricate the antihelix including the superior and inferior crus. The splitted floating eighth rib cartilage was used to fabricate the helix. The height of the helix to be connected to the lobule was trimmed at its lower end and adjusted to receive the lobule and to avoid a slender contour between the constructed auricle and the lobule. The cartilage pieces were assembled with 4-0 clear nylon sutures.

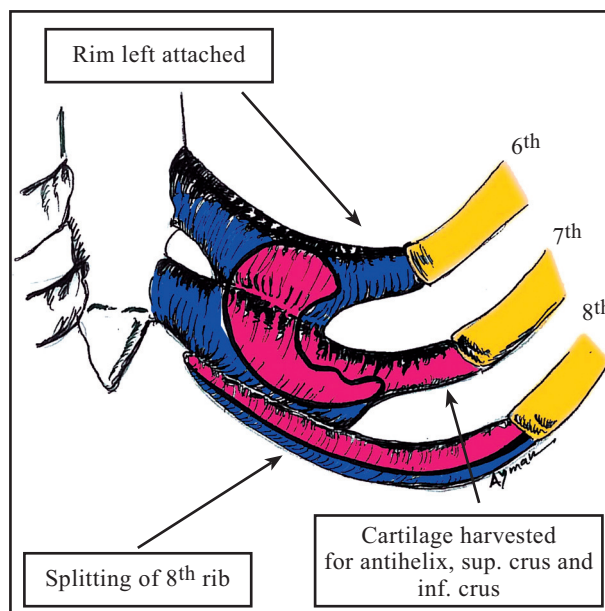


Fig. (1): Splitting of the 8<sup>th</sup> rib preserving rim in its lower margin, also note the preserved rim on the upper part of the synchondrium of 6<sup>th</sup> rib.

The three-dimensional framework is then further refined to accentuate the fine details of the normal ear, recognizing that the framework is made substantially thicker than normal ear cartilage in order to hold its shape, projection and details beneath the overlying skin. At the completion of the framework construction, a segment of unused cartilage is banked in the subcutaneous tissue at the donor site for harvest in the second stage to add more projection to the auricle.

Deflation of the expansion process and then, hemostasis is accomplished with bipolar cautery and is checked meticulously before placement of the framework. The constructed cartilage framework then inserted into the subcutaneous pocket and is seated in its appropriate symmetrical position. The tail of the framework was set into the lobule and the skin incision was sutured. Two suction drains (19-gauge butterfly IV lines) are placed deep to the concha and sulcus and connected to 50cc syringes working as vacuum tubes. Additional bolster sutures are placed to the concha, antihelix and helical contours to further enhance the skin/cartilage coaptation and to snug the skin into the sulci of the framework. The drains were removed on the fourth to the seventh postoperative day when the amount of drainage was less than 1 cc/8 hours and bolsters are removed after 14 days.

## 2- Second Stage: (framework elevation and augmentation of projection).

The second stage reconstruction is generally performed 4-6 months after the first operation. Skin incision was made several millimeters outside the posterior margin of the auricle. In the upper part of the framework the incision is made just anterior to the hair line to preserve its integrity. The dissection was performed beneath the framework and above the fascial plane until the correct amount of projection is achieved. The banked cartilage graft was retrieved through the previous incision, shaved and shaped to mimic the posterior conchal wall, then, wedged in a tunnel created under the mastoid fascia to the underside of the elevated framework to increase the projection. This eliminates the need for axial temporoparietal fascia or occipitalis fascia turn over coverage which is reserved for salvage procedures. The scalp and mastoid skin were advanced forward to reach near the posterior sulcus. The remaining raw surface of the posterior auricular region and the upper part of the anterior surface of the frame-

work were covered with a split-thickness skin graft.

Tragal reconstruction and conchal deepening and making adjustments for symmetry were done when definition of the conchal floor and the tragus were lacking. If needed, we did it in a separate stage. The floor can be deepened while advancing a skin flap around a tragal cartilage support harvested from the contra-lateral concha. The deepened conchal floor was then covered with a full thickness skin graft removed from the opposite post-auricular sulcus.

## RESULTS

A total of 16 ears in 15 consecutive patients with microtia, ranging in age from 6 to 23 years were treated between January 2005 to June 2008. Unilateral microtia was present in 14 patients, while bilateral deformity was present in one patient. There was a predominance of the right side in unilateral cases (n=11 patients) in contrast with 3 with left-sided deformity. The follow-up period was 6 months to 3 years. The results were evaluated by ear contour and position, quality of convolutions, projection of the ear and patient or family satisfaction. Fourteen auricles presented good acceptable ear contour after ear reconstruction (Figs. 2,3). No donor site complications either primary or delayed encountered in this series apart from hypertrophic scars in two cases. One case showed blunted convolutions, improper projection of the auricle in two cases and helical notching in one. Minor cosmetic complications were hypertrophic scars in two cases. They were present in the postauricular area and in the chest donor site and responded to the treatment with topical steroids. There was no total skin flap loss over the framework and no infection. However, skin breakdown and partial cartilage exposure occurred in one case in a small area about one cm which was superficial and healed spontaneously. No hematoma, as meticulous hemostasis and suction drainage with superadded bolster sutures were routine in our cases.

## DISCUSSION

Microtia is a relatively rare deformity, it occurs in approximately 1 in 8000 births. Males are affected more than females, at a 2.5:1 ratio. Unilateral cases outnumber bilateral by a 4:1 ratio, with a more predilection for the right side [23,24]. Our patients showed similar picture of distribution.



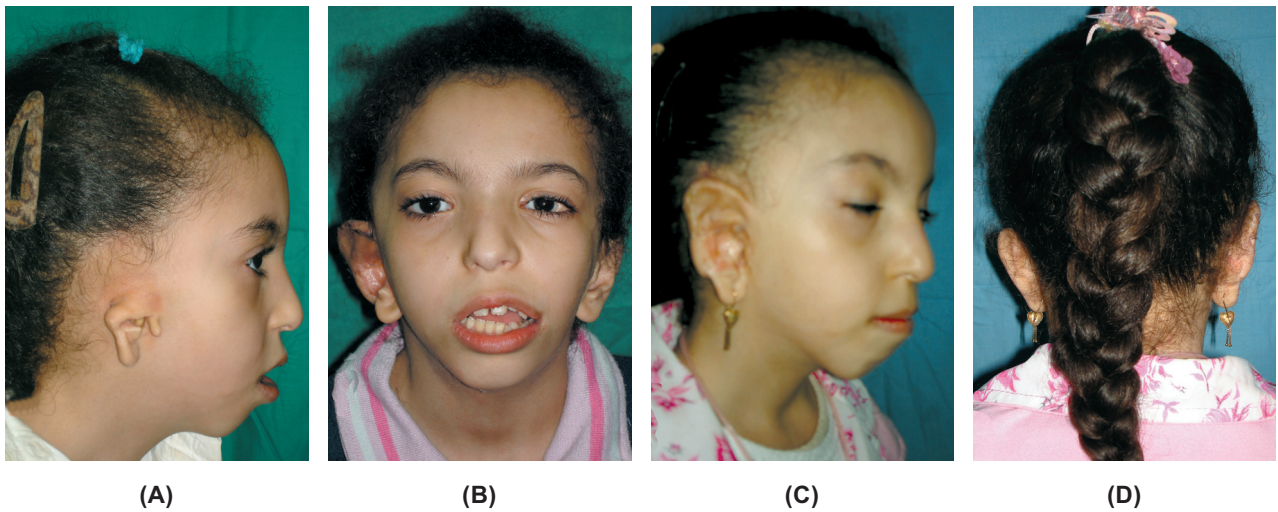

Fig. (2): Above (A) preoperative, small concha type microtia of right side. (B), postoperative, one month after the second stage and six months after first stage. Below (C & D) one year postoperative.

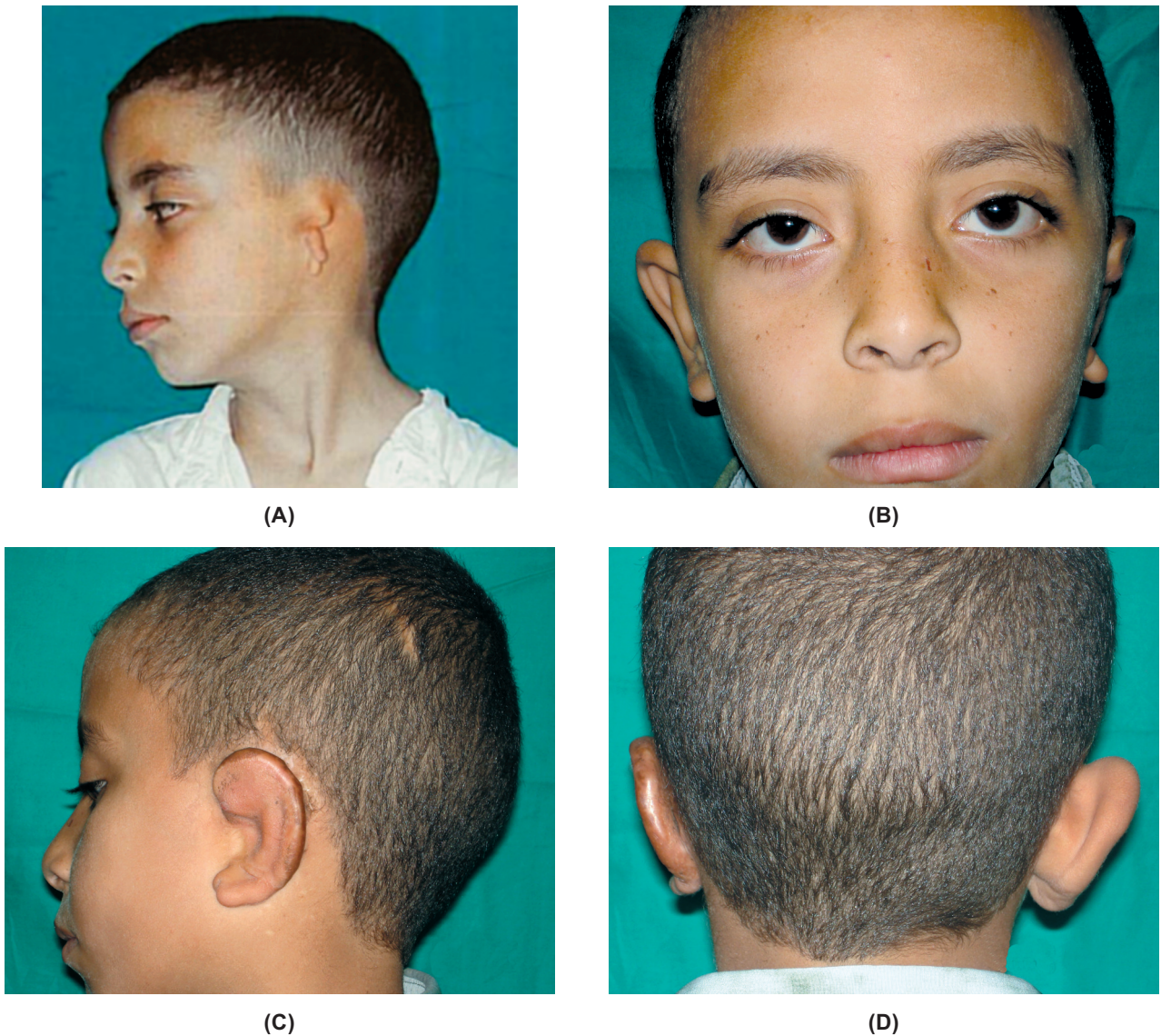

Fig. (3): (A) preoperative view of lobular type microtia of left side (B, C, D) one year postoperative.

The optimal age to perform microtia repair is a matter of debate. Some of the influencing factors include maturity of the ear, available rib cartilage and psychosocial issues. The usual age is between 6 and 8 years. Brent usually begins repair at age 6 in girls and in boys recommends waiting longer, up to age 10 [24]. Nagata, on the other hand, commences surgery at 10 years of age, or when the chest circumference at the level of the xiphoid is at least 60cm [13]. This relatively late starting age may correlate with the greater amount of rib cartilage necessary to perform Nagata's technique of repair. In our study, we started auricular reconstruction at age of 6 years unless the patient presented later which is a common incidence in our community.

Ear reconstruction is a complex multistage procedure. The stages range in number from two to four, with about 3-6 months' separation in between. Although a variety of surgical strategies have been advocated over the years, reconstruction with autogenous rib cartilage graft, as established and modified by Tanzer, Brent and others, despite their potential for donor site complications, remains the gold standard technique [25,26]. Various modifications and refinements in, costal cartilage harvest, carving, implantation and positioning, were evolved over time to avoid the drawbacks and to improve the aesthetic outcome [22].

In his pioneering work to minimize the operative stages, Nagata accomplishes microtia reconstruction in two stages [9-13]. The first stage involves auricular framework fabrication from the ipsilateral rib cartilage (from 6<sup>th</sup> through 9<sup>th</sup> ribs), tragus construction and lobule transposition. The framework is assembled with the use of stainless steel wire sutures. Since his technique requires the harvest of a significant amount of rib cartilage, Nagata leaves most of the perichondrium in situ to minimize the anterior chest wall deformity by stimulating cartilage regeneration. In addition, the significant amount of soft tissue manipulation during this stage of reconstruction increases the risk of tissue necrosis, which has been reported to be as high as 14% [14,26]. During the second stage, the auricular framework is elevated with another piece of cartilage taken from the fifth rib through the previous chest incision. Thus, the patient must endure chest wall donor site morbidity a second time. This cartilage wedge graft is covered with a temporo-parietal fascia flap. As a result, additional scalp incisions are required and the temporo-parietal fascia becomes unavailable for salvage of complications. The back of the framework is covered with

an ultra-delicate STSG harvested from the occipital scalp.

In this article we have followed the two-stage technique of Nagata with some modifications to address certain specific aspects that affect the outcome of ear reconstruction and to minimize the donor site morbidity, while keeping minimal numbers of surgical interventions. As an adequate, supple and thin skin envelope is necessary to drape over the multiple convolutions of the framework to render an adequate definitions. So, during the first stage, we routinely perform rapid intraoperative tissue expansion by placing a large Foley catheter balloon into the skin pocket and inflating the balloon during cartilage harvesting and fabrication; this was found to improve the skin pliability and relieves any marginal skin tension.

Ipsilateral or contra-lateral cartilage? Nagata harvests the ipsilateral costal cartilages of the 6<sup>th</sup>, 7<sup>th</sup>, 8<sup>th</sup> and 9<sup>th</sup> ribs, in contrast to the three contralateral costal cartilage segments used in the Brent technique. In this study, we harvested the contralateral side to acquire cartilage of appropriate configuration, as harvesting from the contralateral side provides a better curvature to the graft.

In Nagata technique considerable rib cartilage is needed which may result in a significant chest wall deformity [27]. Nagata emphasizes that the degree of chest wall deformity can be minimized if the perichondrium is left intact at the site of harvest to allow for cartilage regeneration [28]. In an effort to minimize chest wall deformity while harvesting the optimal costal cartilage, we excised only three costal cartilages while preserving a small cartilage rim of the superior margin of the 6<sup>th</sup> rib as in Brent's technique. Also, splitting of the proximal part of the 8<sup>th</sup> rib, leaving part at its lower margin attached in place was always tried. Applying these modifications, we did not encounter any chest wall deformity.

The use of fine-gauge stainless steel wire sutures to assemble the cartilagenous elements of the framework has been associated with a higher incidence of construct notching and wire extrusion [25]. Tanzer reported wire extrusion in 20 of 44 cases [3], while, Firmin reported 8% extrusion rate. In this study, we used clear, 4/0 nylon sutures which has been advocated by Brent with no extrusion reported.

After completion of framework fabrication, an extra-piece of cartilage is banked subcutaneously in the chest wall to be used in the second stage for



augmentation of ear projection. This avoids secondary rib harvesting procedure with its added complications. Nagata uses a crescent-shaped piece of cartilage harvested from the 5<sup>th</sup> rib through the previous chest wall incision which will increase the donor site morbidity. In contrast to Brent, the cartilage graft in our cases was banked subcutaneously in the donor site to avoid the unnecessary tension on the skin covering the framework if the graft was banked in the pocket posterior to the construct.

To obtain an accentuated contour, it is important to secure tight contact between the skin flap and the implanted cartilage framework. Negative-pressure suction drainage has proven to be invaluable in achieving flap coaptation to the framework [20]. Success of the suction drain is improved by careful, airtight closure of the surgical incisions. Brent [6] used a vacuum test tube to create a continuous suction that draws the overlying skin into the framework's convolutions. He reported markedly reduced complications of infection and skin necrosis, which were previously a significant threat when compression mattress sutures were used. Nagata used bolsters affixed with mattress sutures to approximate the skin flaps to the framework. In addition to negative suction drainage, we used bolster type dressings for securing the skin envelope to the framework. Our negative pressure suction drainage system, was a custom design composed of 19-gauge butterfly IV line, 50cc disposable syringe and wooden plate. By doing this, we could prevent loss of cartilaginous definition by diminishing dead space and securing a tight contact between the skin flap and implanted cartilage framework.

To improve ear projection, Brent [4] used a piece of banked costal cartilage placed posteriorly beneath the framework in a fascial pocket. Firmin [14] and Weerda [29] prefer to cover the cartilage wedge with a turnover flap of occipitalis fascia from behind the ear. Nagata [9-13] used a crescent-shaped piece of cartilage harvested from the fifth rib through the previous chest wall incision. A temporoparietal fascia (TPF) flap was then elevated and tunneled subcutaneously to cover the posterior surface of the cartilage graft, the reconstructed auricle and the mastoid surface. However, a visible scar on the temporal hair-bearing region remained as a drawback. In addition, this does preclude the TPF flap for future salvage procedures. In our cases, the banked cartilage graft was wedged in a tunnel created under the mastoid fascia to the underside of the elevated framework. This elimi-

nates the need for temporoparietal fascia or occipital fascia turn over coverage.

In autogenous microtia repair, one of the main problems is hair bearing skin overlying the site of the helix. This results in hair growth on the construct, which substantially detracts from the final result. To solve this problem, many authors recommend manual depilation, which produced subsequent scarring [1]. Brent has recommended electrolysis or laser hair removal of the scalp flap before commencement of the ear reconstruction or resurfacing the area with a skin graft [4,8]. Nagata recommends the use of ultra-delicate split-thickness scalp graft over the TPF to precisely position the reconstructed ear and reposition the hairline [30]. To address this problem, we incise the skin flap just anterior to the hairline, undermine the scalp skin at the subdermal plane and reposition the hairline into its normal position preserving the integrity of the posterior hairline and then the helix in this area was covered with a medium thickness skin graft. This method gives satisfactory results, but we believe that, this area still needs a more sophisticated technique to get better results. In conclusion, the results of the two-stage technique with the described modifications produced satisfactory aesthetic results and minimal donor site morbidity with reduced number of operative stages.

## REFERENCES

- 1- Walton R.L. and Beahm E.K.: Auricular Reconstruction for Microtia: Part II. Surgical Techniques. *Plast. Reconstr. Surg.*, 110: 234-249, 2002.
- 2- Tanzer R.C.: Total reconstruction of the auricle: The evolution of a plan of treatment. *Plast. Reconstr. Surg.*, 47: 523, 1971.
- 3- Tanzer R.C.: Microtia: A long-term follow-up of 44 reconstructed auricles. *Plast. Reconstr. Surg.*, 61: 161, 1978.
- 4- Brent B.: The correction of microtia with autogenous cartilage grafts I: The classic deformity. *Plast. Reconstr. Surg.*, 66: 1, 1980.
- 5- Brent B.: The correction of microtia with autogenous cartilage grafts II: Atypical and complex deformities. *Plast. Reconstr. Surg.*, 66: 13, 1980.
- 6- Brent B.: Auricular repair with autogenous rib cartilage grafts: Two decades of experience with 600 cases. *Plast. Reconstr. Surg.*, 90: 355, 1992.
- 7- Brent B.: Modification of the stages in total reconstruction of the auricle: Parts I to IV (Discussion). *Plast. Reconstr. Surg.*, 93: 267, 1994.
- 8- Brent B.: Technical advances in ear reconstruction with autogenous rib cartilage grafts: Personal experience with 1200 cases. *Plast. Reconstr. Surg.*, 104: 319, 1999.

- 9- Nagata S.: A new method of total reconstruction of the auricle for microtia. *Plast. Reconstr. Surg.*, 92: 187, 1993.
- 10- Nagata S.: Modification of the stages in total reconstruction of the auricle: Part I. Grafting the three-dimensional costal cartilage framework for lobule-type microtia. *Plast. Reconstr. Surg.*, 93: 221, 1994.
- 11- Nagata S.: Modification of the stages in total reconstruction of the auricle: Part II. Grafting the three-dimensional costal cartilage framework for concha-type microtia. *Plast. Reconstr. Surg.*, 93: 231, 1994.
- 12- Nagata S.: Modification of the stages in total reconstruction of the auricle: Part III. Grafting the three-dimensional costal cartilage framework for small concha-type microtia. *Plast. Reconstr. Surg.*, 93: 243, 1994.
- 13- Nagata S.: Modification of the stages in total reconstruction of the auricle: Part IV. Ear elevation. *Plast. Reconstr. Surg.*, 93: 254, 1994.
- 14- Firmin F.: Ear reconstruction in cases of typical microtia: Personal experience based on 352 microtia ear corrections. *Scand. J. Plast. Reconstr. Surg. Hand Surg.*, 32: 35, 1998.
- 15- Park C., Lee T.J., Shin K.S. and Kim Y.W.: A single-stage two-flap method of total ear reconstruction. *Plast. Reconstr. Surg.*, 88: 404, 1991.
- 16- Park C.: Subfascial expansion and expanded two-flap method for microtia reconstruction. *Plast. Reconstr. Surg.*, 106: 1473, 2000.
- 17- Jiang H., Pan B., Lin L., Cai Z. and Zhuang H.: Ten-year experience in microtia reconstruction using tissue expander and autogenous cartilage. *Int. J. Pediatr. Otorhinolaryngol.*, 72 (8): 1251, 2008.
- 18- Han K. and Son D.: Osseointegrated alloplastic ear reconstruction with the implant-carrying plate system in children. *Plast. Reconstr. Surg.*, 109: 504, 2002.
- 19- Room T. 3<sup>rd</sup> and Reitzen S.D.: Aesthetic microtia reconstruction with Medpor. *Facial Plast. Surg.*, 24 (1): 120, 2008.
- 20- Cho B.C. and Lee S.H.: Surgical Results of Two-Stage Reconstruction of the Auricle in Congenital Microtia Using an Autogenous Costal Cartilage Alone or Combined with Canalooplasty. *Plast. Reconstr. Surg.*, 117 (3): 936, 2006.
- 21- Leach J.L. Jr., Jordan J.A., Brown K.R. and Biavati M. J.: Techniques for improving ear definition in microtia reconstruction. *Int. J. Pediatr. Otorhinolaryngol.*, 48: 39, 1999.
- 22- Zim S.A.: Microtia reconstruction: An update. *Current opinion in otolaryngology & Head and Neck Surgery*, 11: 275, 2003.
- 23- Tollefson T.T.: Advances in the treatment of microtia. *Current Opinion in Otolaryngology & Head and Neck Surgery*, 14: 412-422, 2006.
- 24- Kelley P.E. and Scholes M.A.: Microtia and Congenital Aural Atresia. *Otolaryngol. Clin. N. Am.*, 40: 61-80, 2007.
- 25- Brent B.: The team approach to treating the microtia atresia patient. *Otolaryngol. Clin. North Am.*, 33 (6): 1353, 2000.
- 26- Brent B.: Microtia repair with cartilage grafts: A review of personal experience with 1000 cases. *Clinics in Plast. Surg.*, 29: 257, 2002.
- 27- Ohara K., Nakamura K. and Ohta E.: Chest wall deformities and thoracic scoliosis after cartilage graft harvesting. *Plast. Reconstr. Surg.*, 99: 1030, 1997.
- 28- Kawanabe Y. and Nagata S.: A new method of costal cartilage harvest for total auricular reconstruction. Part I: Avoidance and prevention of intraoperative and post-operative complications and problems. *Plast. Reconstr. Surg.*, 117: 2018, 2006.
- 29- Weerda H.: Classification of congenital deformities of the auricle. *Facial Plast. Surg.*, 5: 385, 1988.
- 30- Nagata S.: Microtia: Auricular reconstruction. In C.A. Vanderkolk (ed.), *Plastic surgery: Indications, Operations and Outcomes*. Vol. 2. St. Louis: Mosby, Pp. 1023-1056, 2000.